


Follow-up of Toxoplasmosis during Pregnancy: Ten-Year Experience in a University Hospital in Southern Brazil

Acompanhamento da toxoplasmose durante a gravidez: uma década de experiência em um hospital universitário no Sul do Brasil

Amanda Andrade Diesel¹ Suzana de Azevedo Zachia¹ Ana Lúcia Letti Müller¹ 
Amanda Vilaverde Perez¹ Flavio Antonio de Freitas Uberti² José Antônio de Azevedo Magalhães¹

¹Fetal Medicine Group, Hospital de Clínicas de Porto Alegre, Universidade Federal do Rio Grande do Sul, Porto Alegre, Rio Grande do Sul, Brazil

²Pediatrics Service, Hospital de Clínicas de Porto Alegre, Universidade Federal do Rio Grande do Sul, Porto Alegre, Rio Grande do Sul, Brazil

Address for correspondence Amanda Andrade Diesel, Master student, Postgraduate Program in Gynecology and Obstetrics, Medical School, Universidade Federal do Rio Grande do Sul, Rua Ramiro Barcelos, 2350/ room 1125, 90035-903, Porto Alegre, RS, Brazil (e-mail: amanda.diesel@hotmail.com).

Rev Bras Ginecol Obstet 2019;41:539–547.

Abstract

Objective To describe a population of pregnant women diagnosed with toxoplasmosis and their respective newborns, describing the hospital protocol for treatment and follow-up.

Methods Retrospective cohort of pregnant women with acute toxoplasmosis infection and risk of transplacental transmission who were sent to the Fetal Medicine Group of Hospital de Clínicas de Porto Alegre (HCPA) between - January 1, 2006 and December 31, 2016. All patients with confirmed disease were included. The diagnostic protocol and treatment were applied; a polymerase chain reaction (PCR) analysis of the amniotic fluid was used to diagnose toxoplasmosis and determine the treatment. The newborns were followed up at the pediatric outpatient clinic specializing in congenital infection. The patients who were not followed up or were not born in the HCPA were excluded.

Results A total of 65 patients were confirmed to have gestational toxoplasmosis; 40 performed amniocentesis, and 6 (15%) were identified as having positive PCR in the amniotic fluid. In five of those cases, this result associated with the gestational age defined the triple therapy during pregnancy, and in one case, it defined the monotherapy (advanced gestational age). A total of 4 of these newborns were treated from birth with triple therapy for 10 months, 1 was not treated (due to maternal refusal), and 1 progressed to death within the first 54 hours of life due to complications of congenital toxoplasmosis. Of the 34 remaining cases with a negative PCR, 33 were treated with monotherapy and 1 was treated with triple therapy (ultrasound findings); of these children, 9 (26.5%) presented negative immunoglobulin G (IgG), 24 (70.6%) presented

Keywords

- ▶ toxoplasmosis
- ▶ congenital infection
- ▶ fetal infection
- ▶ congenital toxoplasmosis
- ▶ pharmacodermia

 Ana Lúcia Letti Müller's ORCID is <https://orcid.org/0000-0003-1214-5664>.

received
July 21, 2018
accepted
August 6, 2019

DOI <https://doi.org/10.1055/s-0039-1697034>.
ISSN 0100-7203.

Copyright © 2019 by Thieme Revinter Publicações Ltda, Rio de Janeiro, Brazil

License terms



positive IgG (but none presented positive immunoglobulin M [IgM]), and 1 (2,9%) presented alterations compatible with congenital disease and started treatment with the triple therapy soon after birth. Out of the total sample of 60 patients, among the 25 who did not perform amniotic fluid PCR, 5 were treated with triple therapy (ultrasound findings/prior treatment) and 20 patients were submitted to monotherapy; only two newborns underwent treatment for congenital toxoplasmosis. Among the 65 cases of gestational toxoplasmosis, 6 (9,2%) children had a diagnosis of congenital toxoplasmosis, and 2 patients with triple therapy felt severe adverse effects of the medications.

Conclusions The present study suggests that research on PCR screening of the amniotic fluid may be useful to identify patients with a higher potential for fetal complications, who may benefit from the poly-antimicrobial treatment. Patients with negative PCR results must continue to prevent fetal infection with monotherapy, without risk of fetal or maternal impairment.

Resumo

Objetivo Descrever uma população de pacientes diagnosticadas com toxoplasmose na gestação e seus respectivos recém-nascidos, relatando o protocolo do hospital durante o tratamento e seguimento.

Métodos Coorte retrospectiva de gestantes com infecção aguda por toxoplasmose e risco de transmissão transplacentária, encaminhadas para acompanhamento pelo Grupo de Medicina Fetal do Hospital de Clínicas de Porto Alegre (HCPA) entre 1º de janeiro de 2006 e 31 de dezembro de 2016. Todas as pacientes com doença confirmada foram incluídas. O protocolo de diagnóstico e tratamento foi aplicado; uma análise da reação em cadeia da polimerase (RCP) no líquido amniótico foi utilizada para diagnosticar a toxoplasmose e determinar o tratamento. Os recém-nascidos foram acompanhados no ambulatório de pediatria especializado em infecções congênitas. Pacientes que não foram seguidas ou cujo parto não foi feito no hospital foram excluídas.

Resultados A toxoplasmose gestacional foi confirmada em 65 pacientes; 40 realizaram amniocentese, e 6 (15%) foram identificadas com RCP positiva no líquido amniótico. Este resultado associado à idade gestacional definiu a terapia tríplice durante a gestação em 5 casos, e a monoterapia em 1 caso (por idade gestacional avançada). Quatro destas crianças foram tratadas desde o nascimento com terapia tríplice por 12 meses, 1 não foi tratada (por recusa materna), e 1 evoluiu com óbito dentro das primeiras 54 horas de vida devido a complicações da toxoplasmose congênita. Dos 34 casos remanescentes com RCP negativa, 33 foram tratados com monoterapia, e 1 foi tratado com terapia tríplice (por achados ultrassonográficos); destes recém-nascidos, 9 (26,5%) tiveram imunoglobulina G (IgG) negativa, 24 (70,6%) tiveram IgG positiva, mas nenhum apresentou imunoglobulina M (IgM) positiva, e 1 (2,9%) apresentou alterações compatíveis com doença congênita e iniciou a terapia tríplice logo após o nascimento. Entre as 25 pacientes que não fizeram RCP no líquido amniótico, 5 foram tratadas com terapia tríplice (por achados ultrassonográficos/tratamento prévio) e 20 receberam monoterapia; somente 2 recém-nascidos receberam tratamento para toxoplasmose congênita. Entre os 65 casos de toxoplasmose gestacional, 6 (9,2%) recém-nascidos tiveram o diagnóstico de toxoplasmose congênita. Um total de 2 pacientes submetidas à terapia tríplice apresentaram efeitos adversos severos das medicações utilizadas.

Conclusão Este estudo sugere que a triagem da RCP para toxoplasmose do líquido amniótico pode ser útil no rastreamento de pacientes com maior potencial para complicações fetais, que podem se beneficiar do tratamento poli antimicrobiano. Pacientes com RCP negativa devem continuar a prevenir a infecção fetal com monoterapia, sem risco de comprometimento fetal ou materno.

Palavras-chave

- ▶ toxoplasmose
- ▶ infecção congênita
- ▶ infecção fetal
- ▶ toxoplasmose congênita
- ▶ farmacodermia

Introduction

Toxoplasmosis is caused by the protozoan *Toxoplasma gondii*, and has domestic and wild cats as the definitive host. Infection by this parasite in humans may occur through water and foods contaminated by oocysts, or it may be congenital, when the pregnant woman becomes contaminated during pregnancy and the etiologic agent crosses the placental barrier.^{1,2}

It is estimated that 1/3 of the world population is infected, but prevalence varies in different regions. In Brazil, seroprevalence varies between 42% and 90% of the population. In the congenital form, the worldwide incidence is also variable, and it is estimated that between 1 and 10 children are born infected for every 10,000 live births. In Brazil, according to data from the Ministry of Health, there are studies showing rates between 3 and 20 cases per 10,000 live births.^{3,4}

The disease is usually asymptomatic in most patients. However, in the congenital form, sequelae in the fetus can be severe and irreversible. Some infected by the intrauterine parasite can be born without complications and present changes during the first year of life, in childhood, or even in adult life. Among the clinical findings, the following stand out: cerebral calcifications, chorioretinitis, blindness, delayed neuropsychomotor development, microcephaly, hydrocephalus, bulging fontanelle, meningoencephalitis, strabismus, hepatosplenomegaly, rash, petechiae, jaundice, and pneumonia.⁴⁻⁸

During the prenatal period, serological screening can be performed, making it possible to identify susceptible patients and perform primary prevention. It also enables the detection of acute infection by *T. gondii* and guides treatment to reduce the probability of fetal transmission, which is close to 40% in untreated women. The incidence of fetal infection is higher when the disease is acquired in the third trimester compared with the first trimester, but the severity of the involvement is greater when maternal infection occurs in the first trimester.^{1,3,9-12}

In pregnant women with exams that suggest acute infection, it is necessary to determine whether there is any impairment to the fetus. In these situations, one can perform amniocentesis to detect the presence of the parasite's DNA in the amniotic fluid through the polymerase chain reaction (PCR) method. The recommended gestational age for amniocentesis is over 18 weeks. A detailed ultrasound evaluation should also be performed to detect possible changes, such as hydrocephaly, microcephaly and intracranial calcifications. When cases of acute infection in pregnancy are identified, it is possible to perform treatments and reduce the risks of fetal complications.¹³⁻¹⁵ In the presence of changes in the ultrasound examination, the procedure with an evaluation of the amniotic fluid followed by treatment is recommended.

There are difficulties in defining the diagnosis of congenital infection in newborns, even in cases in which the treatment was performed during gestation, because the anti-toxoplasma immunoglobulin G (IgG) levels identified may be those transmitted passively by the mother, and do not represent the endogenous antibodies of the child. In

cases of diagnostic doubts or confirmed congenital infection, it is important to refer such patients to follow-up in a specialized service.^{3,4}

In Brazil, the Ministry of Health has established a protocol to perform the serological screening and the follow-up of each case diagnosed. In endemic regions, the recommendation is to carry out the screening with immunoglobulin M (IgM) and IgG at the first prenatal visit. In seronegative pregnant women, they recommend repeating the titers quarterly. For those with positive IgM and IgG titers, the research should continue with the IgG avidity test, and if the result indicates a recent infection, the patient should be referred to a specialized high-risk prenatal service.^{4,13,14} All patients with diagnosis of toxoplasmosis in pregnancy and ultrasound findings have indication of triple therapy with sulfadiazine/pyrimethamine/foinic acid according to the gestational age. For the other patients, the medication of choice is spiramycin. Treatment is often initiated prior to performing the ultrasonography and further investigation because of the delay in access to the specialized service.

The aim of the present study was to describe a population of pregnant women at risk for transplacental transmission of toxoplasmosis, as well as their newborns, to identify the incidence of the congenital form of the disease, while also describing the protocol of Hospital de Clínicas de Porto Alegre (HCPA), Southern Brazil, for the follow up of these cases from pre-natal care up to the first year of life of the newborns, to determine the placental transmission through PCR in the amniotic fluid, and to describe the treatments performed, the maternal adverse effects, and the complications in the fetuses and children.

Methods

A retrospective cohort was performed based on the analysis of medical records. The study period was between January 1, 2006, and December 12, 2016. The study population was composed of pregnant women referenced from basic units of the Brazilian unified health system to the Fetal Medicine Group of the HCPA with suspected toxoplasmosis infection, and their respective children. All of the pregnant women referred to the study repeated the IgM and IgG serological tests for toxoplasmosis at the first visit to the outpatient clinic, and were also asked to test the avidity for IgG anti-toxoplasma. Patients with positive serology for IgM and IgG and low IgG avidity were confirmed with acute toxoplasmosis. Those with positive serology and high IgG avidity after the 16th week of pregnancy were considered cases of acute disease, as well as patients with positive IgM and IgG who did not undergo the IgG avidity test. The inclusion criterion was patients with confirmed/considered acute disease, and the exclusion criteria were patients who were lost to follow-up in the fetal medicine outpatient clinic, and those who were not born in the HCPA. Patients with acute toxoplasmosis during pregnancy could choose to perform a fetal infection investigation through amniocentesis to detect the DNA of the parasite in the amniotic fluid through PCR. Amniocentesis was performed in patients with more than 16 weeks of

gestational age (due to their availability to undergo the exam). The method was used to indicate the treatment according to the protocol of the Fetal Medicine Group of the HCPA, and the pregnant women with positive PCR, considered as having the fetal disease, would be treated with the triple therapy (sulfadiazine/pyrimethamine/fofinic acid), while those with negative results, considered as not having the fetal disease, would be treated only with spiramycin (or azithromycin in case spiramycin was not available) to minimize the adverse effects. The patients also underwent serial ultrasonography to evaluate the fetal anatomy. The ultrasound and the collection of amniotic fluid were performed by the same professional. Patients undergoing triple therapy underwent blood counts periodically (every 15 to 30 days), and were monitored for adverse side effects.

The pregnant patients who did not undergo amniocentesis were treated with spiramycin and serial ultrasonography. In cases in which fetal impairment was suspected, the treatment was modified to triple therapy. The children of these pregnant women were followed up at the congenital infections outpatient clinic, where they performed clinical, neurological and ophthalmologic evaluations, serological and laboratory tests (IgG and IgM), cerebrospinal fluid examination, and imaging tests (ultrasound and tomography) of the central nervous system. The follow-up of these newborns occurred from the neonatal period until the confirmation, or not, of congenital infection. The maternal variables studied were: maternal age, ethnicity, schooling, parity, gestational age at the time of the tests, serological results (IgM, IgG and avidity for IgG), type of treatment for toxoplasmosis, and adverse events. The variables of the newborns and children studied were: sex, birth weight, serological IgG and IgM results, congenital toxoplasmosis, treatment performed and period, and sequelae. The data analysis was performed using the Stata (StataCorp, LLC, College Station, TX, US) software, version 13.0; the categorical variables were described in absolute and relative frequencies, and the numerical variables were presented through the mean, standard deviation and amplitude. The study was approved by the Ethics in Research Committee of the HCPA (Report Number: 1.731.318). The authors signed a commitment form for the use of the medical records. All patients were advised about the disease, the risk of fetal and child compromise in the long term, the possibilities of the treatment and its risks, and the importance of postnatal follow-up. They consented to the use of the data in the research.

Results

During the study period, 2,110 new consultations were performed at the fetal medicine outpatient clinic of the HCPA, including suspected malformations and syndromes. Of these, 171 (8.1%) patients were referred due to suspicion of fetal infection. Among the infectious cases, suspected toxoplasmosis during gestation was the main cause of referral to the outpatient clinic, accounting for 67.3% (115 patients) of the cases. The other referrals were: 13.4% (23

with suspected syphilis during gestation, and 19.3% (33) with other infections during gestation (►Fig. 1).

Out of the 115 patients referred for suspected gestational toxoplasmosis, 16 (13.9%) were excluded for not attending the follow-up in the outpatient clinic, and 33 (28.7%) were evaluated, and it was confirmed that they had a disease prior to the current gestation; for this diagnosis, pre-pregnancy tests were used in the analysis (data from previous pregnancies or pre-conception evaluation), as well as the results of new serological tests (IgM and IgG repetition, avidity test for IgG collected before the 16th week, with high avidity). Among these 115 patients, there was only 1 case (0.9%) of false positive IgM; this patient repeated the serologies, and both tests presented negative results. Thus, there were 65 (65.6%) pregnant women referred with gestational toxoplasmosis.

Given the strong suspicion or the diagnosis of acute infection in pregnancy due to toxoplasmosis, the HCPA protocol indicates the possibility of investigating fetal infection through amniocentesis, explaining the risks and benefits of follow-up research. In the population of interest of this study, 61.5% (40 cases) of the patients chose to perform the fetal infection investigation through the invasive procedure, and amniocentesis to collect amniotic fluid followed by PCR to detect *T. gondii* DNA. The amniocentesis was performed in patients with gestational age ≥ 16 weeks, and the sample had a mean gestational age of 23 weeks (minimum of 16 and maximum of 31 weeks). Among those who opted for this procedure (40 women), 15% (6 women) had positive PCR and 85% (34 women) had negative results. The result of the PCR associated to gestational age enabled us to define the best treatment option for each case, according to the protocol described in ►Fig. 1.

A total of 6 (15%) cases of positive PCR were identified in the amniotic fluid of the pregnant women; 5 were treated with triple therapy plus spiramycin, and 1, with monotherapy (due to advanced gestational age). Triple therapy for 10 months was the treatment prescribed for 4 of these children; 1 was not treated because the mother refused the treatment, and 1 progressed to death within the first 54 hours of life due to complications of congenital toxoplasmosis. Regarding the incidence of sequelae, one newborn was seriously affected by the congenital disease, and despite the postnatal treatment with triple therapy, the patient developed neurological, ophthalmological and hearing disorders. There was also another case of a newborn who was equally treated due to alteration in the ear test, but without neurological impairment or ocular lesions identified in the long-term follow-up. Among the 34 cases with negative PCR, 33 (97.1%) were treated with monotherapy and 1 (2.9%) was treated with triple therapy (ultrasound finding of hydrops). Of these 34 children, 9 (26.5%) presented negative IgG, 24 (70.6%) presented positive IgG, but none presented positive IgM; 1 (2.9%) presented alterations compatible with congenital disease, and underwent the triple therapy soon after birth. According to the pediatric protocol, newborns with positive IgG were followed up until the titers were negative and the possibility of vertical infection was excluded. The average time

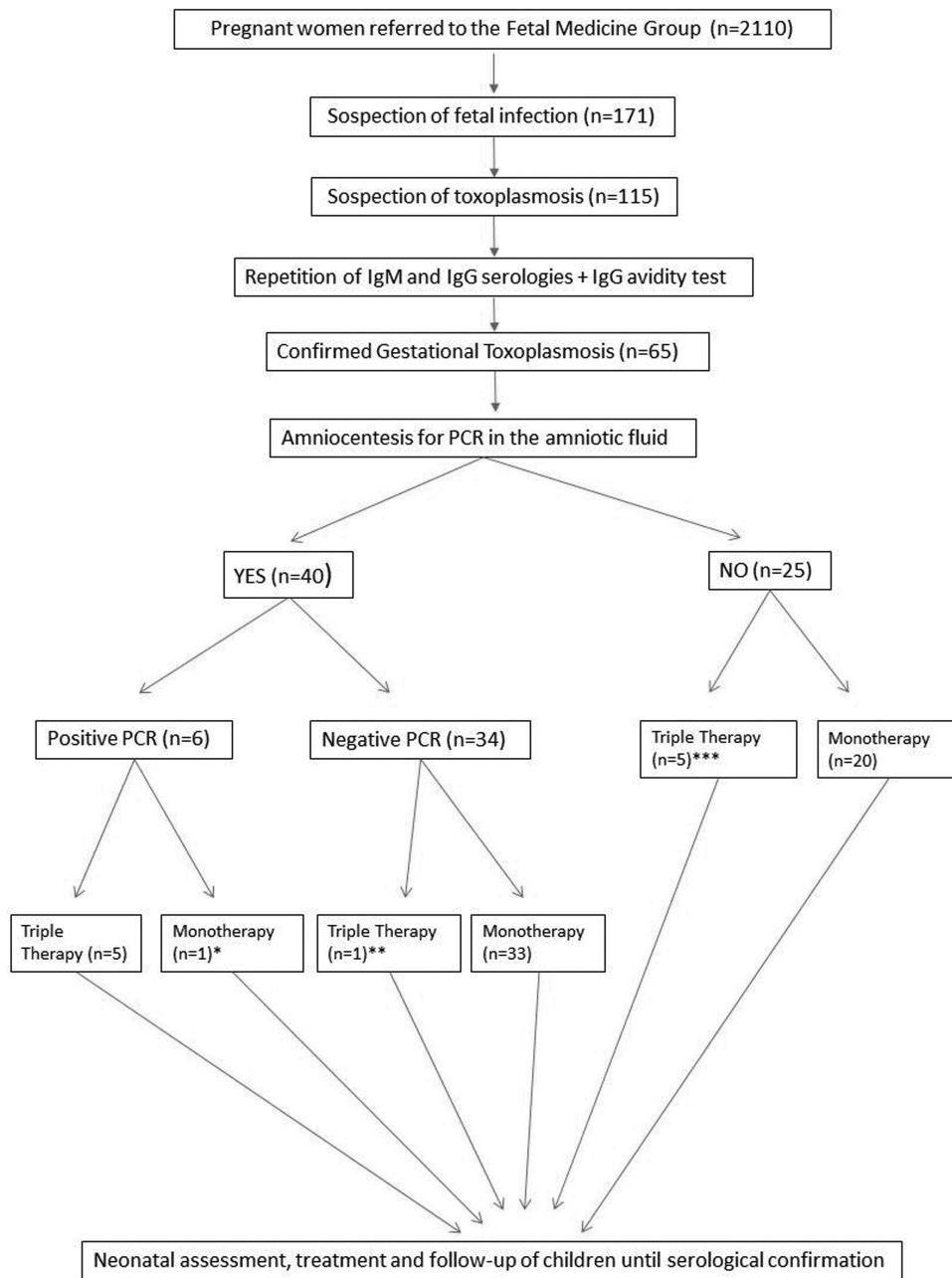


Fig. 1 Diagnosis, treatment and follow-up flowchart of toxoplasmosis infection in pregnancy at Hospital de Clínicas de Porto Alegre (HCPA, 2006–2016). Notes: *Due to advanced gestational age; **due to ultrasound findings; ***due to the maintenance of prior treatment and/or ultrasound alterations compatible with congenital toxoplasmosis.

to reach negative IgG titers in these patients was of 6 months (between 2 and 10 months). Thus, there were 4 (10%) cases of congenital toxoplasmosis out of the 40 cases submitted to amniocentesis (3 cases in the group with positive PCR and 1 in the group with negative PCR). The correlation between maternal and newborn serologies in patients who underwent PCR are described in ► **Table 1**.

A total of 25 (38.5%) patients did not perform the amniocentesis. Out of these, 5 (20%) underwent the triple therapy (due to the maintenance of the prior treatment and/or ultrasound alterations compatible with congenital toxoplasmosis), and 20 (80%) were submitted to monotherapy. In this group, only two newborns underwent treatment for congenital

toxoplasmosis: one due to cerebral calcifications still in the prenatal period, identified by ultrasonography performed at the service, and the other because of high IgG titers. There was also 1 death in this group, but it was related to the associated maternal pathology: the patient had a diagnosis of gestational diabetes, made use of insulin, and intrauterine death occurred in the 37th week.

Of the total 65 cases of gestational toxoplasmosis included in the present study, 6 (9,2%) fetuses had diagnoses of congenital toxoplasmosis.

There were no miscarriages related to toxoplasmosis in the present study. There were no other complications due to amniocentesis either.

Table 1 Correlation between maternal and newborn serologies in patients who underwent the polymerase chain reaction

	Mother IgM and IgG	Mother IgG avidity	PCR in amniotic fluid	Treatment of the mother	Newborn IgM	Newborn initial IgG	Treatment of the newborn	Newborn Follow-up IgG
Positive PCR in the amniotic fluid (n = 6)	R	Low (n = 3); NP (n = 3)	Positive	Monotherapy (n = 1); Triple scheme plus spiramycin (n = 5)	R (n = 2); NR (n = 4)	R	Triple scheme (n = 4); NP (n = 2)	R (n = 2); NR (n = 2); NP (n = 2)*
Negative PCR in the amniotic fluid (n = 34)	R	Low (n = 14); High after 16th week (n = 8); NP (n = 12)	Negative	Monotherapy (n = 33); Triple scheme (n = 1)	NR	NR (n = 9); R (n = 25)	Triple scheme (n = 1); NP (n = 33)	R (n = 1); NR (n = 33)

Abbreviations: IgG, immunoglobulin G; IgM, immunoglobulin M; NR, not reagent; NP, not performed; PCR, polymerase chain reaction; R, reagent. Note: *In one case of positive PCR in the amniotic fluid, no treatment was performed due to the mother's refusal, and in another case, due to newborn death by complications of congenital toxoplasmosis with 54h of life.

The ultrasonographic evaluation performed in the prenatal period detected 6 fetuses with malformations of variable severity, but only 2 were related to vertical infection by the parasite. In both cases, changes were observed in the central nervous system, such as cerebral ventriculomegaly and periventricular calcifications, comprising 5% of all cases (→Fig. 2). These newborns received treatment: one in the group that performed amniocentesis, and one in the group that did not. The other changes were not related to toxoplasmosis.

When calculating the validity of the PCR compared with the gold standard, the diagnosis of congenital toxoplasmosis through the follow-up of the newborn until 1 year with clinical evaluations and complementary tests, we found a sensitivity and a negative predictive value of 100%, a specificity of 92%, and a positive predictive value of 50%.

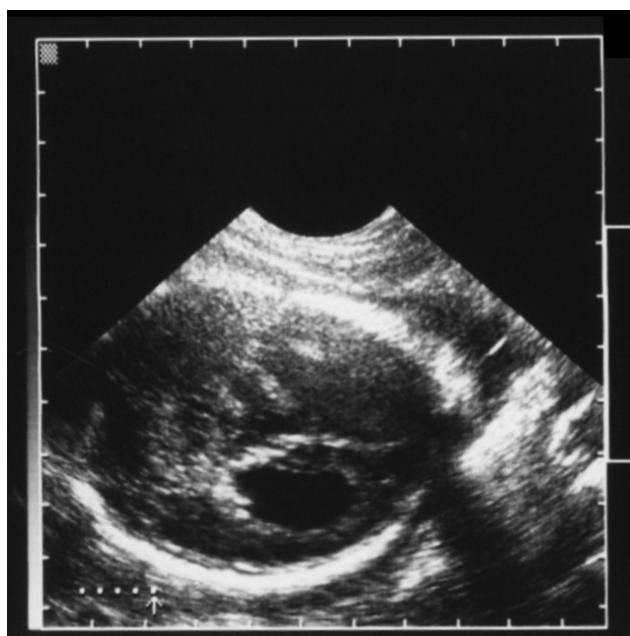

Fig. 2 Ultrasound image of cerebral ventriculomegaly and periventricular calcifications.

Among the patients who underwent prenatal treatment, two cases of serious adverse reactions resulting from the use of the triple therapy were identified. These patients belong to the group that chose not to perform amniocentesis to investigate fetal impairment, but they underwent triple therapy during gestation.

The mother of one of these two cases was a 21-year-old female on her second pregnancy with a sickle cell trait. She presented exams suggestive of gestational toxoplasmosis, but chose not to carry out the fetal investigation and began treatment with the triple therapy. After one month of medication, during the 33rd week of gestation, the patient sought treatment with the following symptoms: diffuse erythematous maculopapular cutaneous rash on the limbs, torso, back and face, odynophagia and fever. The diagnostic hypothesis was drug rash and medullary suppression by the use of sulfadiazine and pyrimethamine without the proper replacement of the folic acid. Upon admission, her hemogram revealed a leukocyte count of 2,030 (1% of myelocytes and 2% of sticks), 9.5 of hemoglobin, and 126,000 platelets. After two days, her leukocyte count increased to 2,680, with 7% of sticks and 2% of metamyelocytes. Despite the treatment with folic acid, she presented clinical worsening, with the following symptoms: jaundice, fever, and abnormal liver enzymes, but with a normal coagulogram, which suggests the hypothesis of acute hepatitis secondary to sulfadiazine and dress syndrome (severe exanthema, systemic symptoms, fever and hepatic alteration) respectively.

The other patient was in her first gestation; she was 19 years old, previously healthy, had examinations suggestive of acute toxoplasmosis during pregnancy, and chose not to undergo the amniocentesis. She had taken azithromycin for 20 days because she had not found spiramycin in pharmacies. After the identification of cerebral calcifications on the ultrasound performed by the fetal medicine team of the HCPA, she was submitted to the triple therapy. After 1 month of taking the medication, during the 33rd week of gestation, she sought care with the following symptomatology: generalized papular cutaneous rash, fever, conjunctivitis and oral ulcers. Varicella and pharmacodermia by sulfadiazine were among the hypotheses for the causes of these symptoms.

Discussion

The indication for serological screening for toxoplasmosis during gestation is not a consensus worldwide due to the varied seroprevalence in different regions. There are countries that advocate screening for all pregnant women, while others only investigate the infection when there are fetal alterations or a clinical condition suggestive of the disease. In Brazil, the Ministry of Health recommends the inclusion of toxoplasma serologies in the examinations requested at the first prenatal visit. Such a measure makes it possible to identify immune pregnant women (only IgG positive), susceptible women (IgM and IgG negative), and those with acute infection and a risk of vertical transmission.^{4,11,13,14,16-18}

The isolated presence of M-type anti-toxoplasma immunoglobulin is not the best approach to identify gestational toxoplasmosis, as found in the present study and in the literature. Additional exams such as IgG anti-toxoplasma dosing and IgG avidity help identify acute infections.¹⁸⁻²⁰ The avidity test for IgG is most useful when it is performed before 16 weeks of gestation. A result of high avidity suggests infection prior to the current pregnancy. Excluding the hypothesis of current acute infection enables a normal prenatal follow-up and eliminates the need for treatment or additional investigations, as occurred in the present study.^{13,14,18,21}

The Brazilian Ministry of Health protocol does not include amniocentesis for the investigation of fetal infection. One can assume that some of the reasons for this decision may be the following: the need for an available qualified professional at public health centers and a laboratory with PCR technology, both of which could be hard to find in Brazil; and the high operational costs and possible maternal-fetal risks.^{4,13,14}

The prenatal patients in the sample who were diagnosed with acute toxoplasmosis infection during gestation were able to choose whether to continue the fetal investigation through amniocentesis to screen for the DNA of the parasite in the amniotic fluid. The mean gestational age for the amniocentesis was 23 weeks, which is in line with the recommended age in the literature.²² Positive PCR results in the amniotic fluid determine which patients require triple therapy.^{17,23}

The ultrasonographic alterations related to vertical transmission, which were only detected in two fetuses in the present study, were: cerebral ventriculomegaly and periventricular calcifications. The findings suggestive of fetal infection by *T. gondii* may arise during gestation, and have already been described in the literature. These findings highlight the importance of serial fetal evaluation with ultrasonography for follow-up counseling and postnatal prognosis.^{3,17,18,24}

Our study identified vertical transmission rates of 9.2% in patients undergoing treatment during pregnancy; other studies have identified prevalence rates of 9.9%.^{25,26} The follow-up of patients with negative PCR results suggests that continuing the prevention of fetal infection with spiramycin monotherapy does not compromise fetal health, and prevents maternal exposure to medications that have potential for complications. The specificity of the PCR found in the present study is similar to that found in the literature, and the negative predictive value of

100% should also be highlighted, despite the small group of patients.^{3,7,19,21,27,28} In the present study, there was a single case in which the newborn, though initially presenting with a negative PCR, was diagnosed as having congenital toxoplasmosis after the follow-up, and went on to develop many types of sequelae from the disease.

The most frequent types of sequelae resulting from congenital toxoplasmosis are ocular, neurological and auditory impairments. Ocular sequelae are the most frequently described in Brazil, and they were also identified in one of the newborns in our sample, who presented with other associated sequelae.^{4,6,7,19,29}

Positive IgM in newborns enables the diagnosis of congenital infection. Positive IgG titers for this disease are evaluated serially. In the present study, the mean time until the IgG titers became negative in non-diseased children was of 6 months, which is similar to that found in other articles. These data reinforce the importance of pediatric follow-ups.^{3,4,20,30,31}

In the present study, the cases of miscarriage due to congenital infection by the parasite, of gestational loss, and of premature rupture of membranes were not observed as complications of having performed amniocentesis. It is known that such an invasive procedure in fetal medicine presents a rate of 1% of risks of complications. These data suggest that the procedure is safe and low-risk when performed by a trained professional.^{2,4,32}

The treatments performed by the pregnant women in the present study correspond to the medications recommended for the disease: triple therapy (sulfadiazine, pyrimethamine and folinic acid) and spiramycin. The use of azithromycin has been identified as an alternative for pregnant women who cannot find spiramycin. This drug is described in the literature as a therapeutic option, especially in immunocompromised patients, but more studies are necessary to validate this approach in pregnant women.^{18,23,26,33-37} Although infrequent, triple therapy may lead to serious complications. Prescribing these medications for all patients who become infected in the third trimester and do not perform the propaedeutic study for fetal research may increase the risk of adverse reactions in individuals who may not need these drugs. The adverse reactions that may occur due to the triple therapy are potentially serious, even life-threatening, as described in the literature and observed in the present study. Therefore, caution should be exercised when selecting which pregnant women will indeed benefit from the treatment, and they must be informed of the importance of taking folinic acid and seeking medical attention quickly if any side effects of the medications are identified.^{13,14,23,38}

The limitations of the present study are the small number of patients and the fact that information was obtained through the retrospective collection of data in medical records, rather than through prospective studies.

In conclusion, epidemiological studies to identify the regional profiles of populations are an important step toward the definition of screening approaches, and of the primary and secondary types of prevention, to reduce the sequelae and complications of congenital toxoplasmosis. The small number

of patients in the present study did not enable us to determine the efficacy of the treatment, but the study suggests that PCR screening in the amniotic fluid may be useful to select the patients with a higher potential for fetal complications who may benefit from the poly-antimicrobial treatment. According to the limited evidence available to date, patients with negative PCR results may continue to prevent fetal infection with spiramycin monotherapy, without compromising fetal or maternal health. Randomized clinical trials are also required to determine the best therapeutic approach when dealing with gestational toxoplasmosis.

Contributors

All of the authors contributed with the project and data interpretation, the writing of the article, the critical review of the intellectual content, and with the final approval of the version to be published.

Conflicts to Interest

The authors have none to disclose.

References

- de Quadros RM, da Rocha GC, Romagna G, de Oliveira JP, Ribeiro DM, Marques SMT. Toxoplasma gondii seropositivity and risk factors in pregnant women followed up by the Family Health Strategy. *Rev Soc Bras Med Trop* 2015;48(03):338–342. Doi: 10.1590/0037-8682-0233-2014
- Souza CdeO, Tashima NT, Silva MA, Tumitan ARP. [Cross-sectional study on toxoplasmosis among female students on a university course in the Presidente Prudente region, State of São Paulo]. *Rev Soc Bras Med Trop* 2010;43(01):59–61. Doi: 10.1590/S0037-8682010000100013
- Pessanha TM, Carvalho M, Pone MVS, Gomes SC Junior. Abordagem diagnóstica e terapêutica da toxoplasmose em gestantes e as repercussões no recém-nascido. *Rev Paul Pediatr* 2011;29:341–347. Doi: 10.1590/S0103-05822011000300006
- Ministério da Saúde. Secretaria de Atenção à Saúde. Departamento de Ações Programáticas Estratégicas. Atenção à Saúde do Recém-Nascido: Guia para os Profissionais de Saúde. 2a ed. Brasília, DF: Ministério da Saúde; 2014
- Lehmann LM, Santos PC, Scaini CJ. Evaluation of pregnant and postpartum women's knowledge about toxoplasmosis in Rio Grande – RS, Brazil. *Rev Bras Ginecol Obstet* 2016;38(11):538–544. Doi: 10.1055/s-0036-1593970
- Mozzatto L, Procianny RS. Incidence of congenital toxoplasmosis in southern Brazil: a prospective study. *Rev Inst Med Trop São Paulo* 2003;45(03):147–151. Doi: 10.1590/S0036-46652003000300006
- Furtado JM, Smith JR, Belfort R Jr, Gattey D, Winthrop KL. Toxoplasmosis: a global threat. *J Glob Infect Dis* 2011;3(03):281–284. Doi: 10.4103/0974-777X.83536
- Fochi MML, Baring S, Spegiorin LCJF, et al. Prematurity and low birth weight did not correlate with anti-toxoplasma gondii maternal serum profiles - a Brazilian report. *PLoS One* 2015;10(07):e0132719. Doi: 10.1371/journal.pone.0132719
- Soares JA, Carvalho SF, Caldeira AP. Profile of pregnant women and children treated at a reference center for congenital toxoplasmosis in the northern state of Minas Gerais, Brazil. *Rev Soc Bras Med Trop* 2012;45(01):55–59. Doi: 10.1590/S0037-86822012000100011
- Lopes-Mori FMR, Mitsuka-Breganó R, Bittencourt LHF, et al. Gestational toxoplasmosis in Paraná State, Brazil: prevalence of IgG antibodies and associated risk factors. *Braz J Infect Dis* 2013;17(04):405–409. Doi: 10.1016/j.bjid.2012.12.003
- Wilking H, Thamm M, Stark K, Aebischer T, Seeber F. Prevalence, incidence estimations, and risk factors of Toxoplasma gondii infection in Germany: a representative, cross-sectional, serological study. *Sci Rep* 2016;6:22551. Doi: 10.1038/srep22551
- Di Mario S, Basevi V, Gagliotti C, et al. Prenatal education for congenital toxoplasmosis. *Cochrane Database Syst Rev* 2015;(10):CD006171. Doi: 10.1002/14651858.CD006171.pub4
- Ministério da Saúde. Secretaria de Atenção à Saúde. Departamento de Ações Programáticas Estratégicas. Gestação de Alto Risco: Manual Técnico. 5ª ed. Brasília, DF: Editora do Ministério da Saúde; 2012
- Federação Brasileira de Ginecologia e Obstetrícia. Manual de Gestação de Alto Risco. São Paulo, SP: FEBRASGO 2011 https://www.febasgo.org.br/images/arquivos/manuais/Manuais_Novos/gestacao_alto-risco_30-08.pdf. Accessed November 16, 2017.
- McLeod R, Lykins J, Noble AG, et al. Management of congenital toxoplasmosis. *Curr Pediatr Rep* 2014;2:166–194. Doi: 10.1007/s40124-014-0055-7
- Flegr J, Prandota J, Sovičková M, Israili ZH. Toxoplasmosis—a global threat. Correlation of latent toxoplasmosis with specific disease burden in a set of 88 countries. *PLoS One* 2014;9(03):e90203. Doi: 10.1371/journal.pone.0090203
- Wallon M, Peyron F, Cornu C, et al. Congenital toxoplasma infection: monthly prenatal screening decreases transmission rate and improves clinical outcome at age 3 years. *Clin Infect Dis* 2013;56(09):1223–1231. Doi: 10.1093/cid/cit032
- American College of Obstetricians and Gynecologists. Practice bulletin no. 151: Cytomegalovirus, parvovirus B19, varicella zoster, and toxoplasmosis in pregnancy. *Obstet Gynecol* 2015;125(06):1510–1525. Doi: 10.1097/01.AOG.0000466430.19823.53
- Tanimura K, Nishikawa A, Tairaku S, et al. The IgG avidity value for the prediction of Toxoplasma gondii infection in the amniotic fluid. *J Infect Chemother* 2015;21(09):668–671. Doi: 10.1016/j.jiac.2015.05.013
- Capobianco JD, Monica TC, Ferreira FP, et al. Evaluation of the Western blotting method for the diagnosis of congenital toxoplasmosis. *J Pediatr (Rio J)* 2016;92(06):616–623. Doi: 10.1016/j.jped.2016.02.014
- Pena LT, Discacciati MG. Importância do teste de avidéz da imunoglobulina G (IgG) anti-Toxoplasma gondii no diagnóstico da toxoplasmose em gestantes. *Rev Inst Adolfo Lutz* 2013;72:117–123. Doi: 10.18241/0073-98552013721551
- Prusa AR, Kasper DC, Pollak A, Olischar M, Gleiss A, Hayde M. Amniocentesis for the detection of congenital toxoplasmosis: results from the nationwide Austrian prenatal screening program. *Clin Microbiol Infect* 2015;21(02):191.e1–191.e8. Doi: 10.1016/j.cmi.2014.09.018
- Bernardo WM, Chinzon M, Chaves FGB. Is sulfadiazine alone equivalent (benefit and harm) to spiramycin to treat acute toxoplasmosis in the first trimester of pregnancy? *Rev Assoc Med Bras (1992)* 2015;61(06):495–496. Doi: 10.1590/1806-9282.61.06.495
- Dhombres F, Friszer S, Maurice P, et al. Prognosis of fetal parenchymal cerebral lesions without ventriculomegaly in congenital toxoplasmosis infection. *Fetal Diagn Ther* 2017;41(01):8–14. Doi: 10.1159/000445113
- Li XL, Wei HX, Zhang H, Peng HJ, Lindsay DS. A meta analysis on risks of adverse pregnancy outcomes in Toxoplasma gondii infection. *PLoS One* 2014;9(05):e97775. Doi: 10.1371/journal.pone.0097775
- Wei HX, Wei SS, Lindsay DS, Peng HJ. A systematic review and meta-analysis of the efficacy of anti-Toxoplasma gondii medicines in humans. *PLoS One* 2015;10(09):e0138204. Doi: 10.1371/journal.pone.0138204
- Teixeira LE, Kanunfre KA, Shimokawa PT, et al. The performance of four molecular methods for the laboratory diagnosis of congenital toxoplasmosis in amniotic fluid samples. *Rev Soc Bras Med Trop* 2013;46(05):584–588. Doi: 10.1590/0037-8682-0095-2013

- 28 Filisetti D, Yera H, Villard O, et al. Contribution of neonatal amniotic fluid testing to diagnosis of congenital toxoplasmosis. *J Clin Microbiol* 2015;53(05):1719–1721. Doi: 10.1128/JCM.02358-14
- 29 Maldonado YA, Read JS; COMMITTEE ON INFECTIOUS DISEASES. Diagnosis, treatment, and prevention of congenital toxoplasmosis in the United States. *Pediatrics* 2017;139(02):e20163860. Doi: 10.1542/peds.2016-3860
- 30 Pomares C, Montoya JG. Laboratory diagnosis of congenital toxoplasmosis. *J Clin Microbiol* 2016;54(10):2448–2454. Doi: 10.1128/JCM.00487-16
- 31 Lago EG, Oliveira AP, Bender AL. Presence and duration of anti-Toxoplasma gondii immunoglobulin M in infants with congenital toxoplasmosis. *J Pediatr (Rio J)* 2014;90(04):363–369. Doi: 10.1016/j.jpmed.2013.12.006
- 32 de Oliveira Azevedo CT, do Brasil PE, Guida L, Lopes Moreira ME. Performance of polymerase chain reaction analysis of the amniotic fluid of pregnant women for diagnosis of congenital toxoplasmosis: a systematic review and meta-analysis. *PLoS One* 2016;11(04):e0149938. Doi: 10.1371/journal.pone.0149938
- 33 Rajapakse S, Weeratunga P, Rodrigo C, de Silva NL, Fernando SD. Prophylaxis of human toxoplasmosis: a systematic review. *Pathog Glob Health* 2017;111(07):333–342. Doi: 10.1080/20477724.2017.1370528
- 34 Avci ME, Arslan F, Çiftçi Ş, et al. Role of spiramycin in prevention of fetal toxoplasmosis. *J Matern Fetal Neonatal Med* 2016;29(13):2073–2076. Doi: 10.3109/14767058.2015.1074998
- 35 Rajapakse S, Chrishan Shivanthan M, Samaranayake N, Rodrigo C, Deepika Fernando S. Antibiotics for human toxoplasmosis: a systematic review of randomized trials. *Pathog Glob Health* 2013;107(04):162–169. Doi: 10.1179/2047773213Y.0000000094
- 36 Castro-Filice LS, Barbosa BF, Angeloni MB, et al. Azithromycin is able to control Toxoplasma gondii infection in human villous explants. *J Transl Med* 2014;12:132. Doi: 10.1186/1479-5876-12-132
- 37 Hotop A, Hlobil H, Gross U. Efficacy of rapid treatment initiation following primary Toxoplasma gondii infection during pregnancy. *Clin Infect Dis* 2012;54(11):1545–1552. Doi: 10.1093/cid/cis234
- 38 Cacoub P, Musette P, Descamps V, et al. The DRESS syndrome: a literature review. *Am J Med* 2011;124(07):588–597. Doi: 10.1016/j.amjmed.2011.01.017