

Comments on: Limitations of HPV DNA Testing in Screening of Cervical Adenocarcinomas

Laurence M. Vaughan¹  Douglas P. Malinowski²

¹Diagnostic Systems, BD Life Sciences, Sparks, MD, United States

²Women's Health and Cancer, BD Life Sciences, Durham, NC, United States

Address for correspondence Laurence M. Vaughan, PhD, BD Life Sciences, 54 Loveton Circle, MC 912, Sparks, MD, 21152, USA (e-mail: laurence.vaughan@bd.com).


Rev Bras Ginecol Obstet 2019;41:357–359.

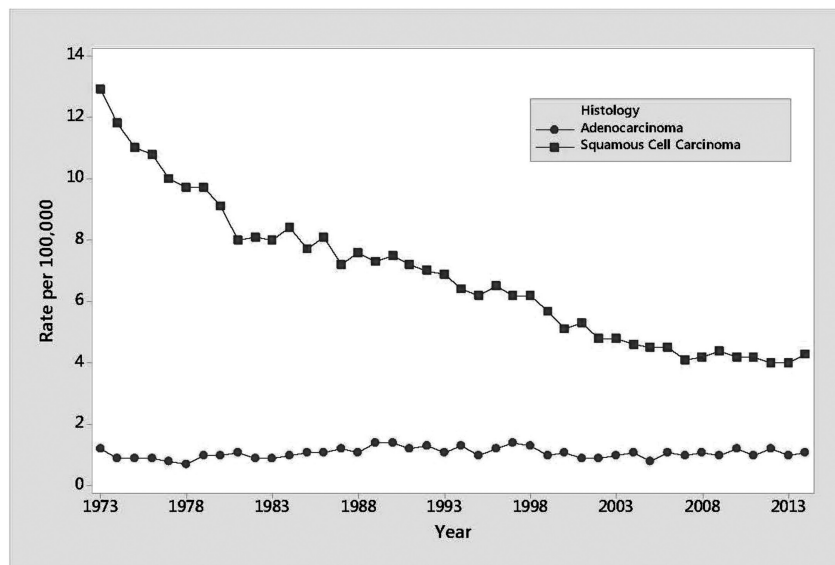
Dear Editor,

We read with interest the article on human papillomavirus (HPV) DNA testing for cervical cancer in Brazil, authored by Zeferino *et al* (Brazilian Association for the Lower Genital Tract Pathology and Colposcopy (ABPTGIC, in the Portuguese acronym), as well as the subsequent letter to the editor, by Dr de Alcantara Segura, and the authors' reply.^{1,2} We agree that detection of adenocarcinomas represents a significant challenge for cervical cancer screening programs. In the United States, squamous cancer rates have seen a decline since the introduction of the Pap smear and molecular testing, but adenocarcinoma rates have remained unchanged (►Fig. 1). Moreover, Australia, which arguably has a best in class vaccination and screening program, is reporting a steady increase in adenocarcinoma rates.³ As Dr. de Alcantara Segura points out, cytology is an insensitive method for screening adenocarcinomas. This has also been shown to be the case in the US, where Katki *et al*⁴ reported that 63% of adenocarcinomas showed normal cytology results. In addition, screening for adenocarcinoma precursors by HPV is clearly less sensitive than squamous cancer precursors, as evidenced by the lack of progress in reducing the adenocarcinoma incidence since the introduction of molecular testing in the 2000s (►Fig. 1). A review of the recently published literature has identified a number of potential causes for the apparent lack of HPV detection within cervical adenocarcinoma, including the following: (i) Historical use of the Hybrid Capture 2 (HC2) assay and an associated higher rate of HPV negative cervical adenocarcinoma cases reported^{5,6}; (ii) low viral load of HPV and detection only with nested polymerase chain reaction (PCR) methods⁷; (iii) L1 vs E6/E7 detection (HPV integration and L1 deletion)^{8,9}; (iv) non-HR HPV genotypes associated with some adenocarcinomas¹⁰; and (v) rare histological subtypes that either have low viral loads or are HPV-negative.^{11,12} There are some cervical adenocarcinoma tissues that appear to be non-HPV derived. Clear cell adenocarcinoma

can arise from prenatal diethylstilbestrol exposure that are not believed to be associated with high-risk HPV infections. Likewise, gastric-type adenocarcinomas are considered to be either HPV-negative, or at least, have very low levels of HPV present.¹³

In particular, target region selection has a significant impact on an HPV DNA test's ability to detect cancers. The majority of assays target the L1 region of the virus, and the gene is prone to deletion during virus integration as disease progresses.^{14–16} Viral integration can also occur early in the disease process and is detected in routine liquid-based cytology specimens of precancer patients.^{14,17} While it has long been reported that E6/E7 target regions are more sensitive than L1, some have argued that this is due to technical difficulties with isolating DNA from fixed tissue (formalin-fixed, paraffin embedded [FFPE]) samples.¹⁸ The use of L1-target region assays, and the older detection methods in the cross-sectional study by de Sanjose *et al*¹⁹ may have contributed to the quoted poor detection rate (62%) of adenocarcinomas. More recent studies using more robust methods and shorter target sequences estimate the rate of HPV-negative cancers at approximately 10% using L1-based PCR assays.^{20,21} While an improvement, it still represents an unacceptably high false-negative rate. Assays that target the E6/E7 genes rarely undergo deletion because of the requirement for E6/E7 gene products in oncogenesis. Thus, assays that target this region of the virus should be more sensitive in detecting cancers. Recent publications confirm that this is in fact the case. Molijn *et al*⁸ reported a 7% increase in adenocarcinoma detection using type-specific E6 PCR versus a very sensitive L1-based SPF10-PCR assay. Lagheden *et al*²¹ also reported the results of a comprehensive analysis of HPV type detection using tissue blocks from the Swedish cancer registry collected from 2002 to 2011. The authors were successful in obtaining 69% of all cell blocks (from 22 different biobanks), and samples were extracted using standardized procedures with hematoxylin & eosin (H&E) confirmatory staining of the first and last sections of each block for re-review. A total of 37 different HPV types were detected using L1 Modified General Primers (MGP) and a

 Laurence M Vaughan's ORCID is <https://orcid.org/0000-0003-2976-3215>.



Source: <https://seer.cancer.gov>

Fig. 1 US cervical cancer rates by histologic type.

Luminex bead readout. Of the 2,932 retrieved blocks, 2,850 (97%) gave valid PCR results (beta globin internal cellularity control detected). A total of 527 (18%) samples were found to be HPV-negative but approximately 8% of these were negative for invasive cancer on reviewing the histology, and were thus excluded from the analysis. The DNAs from the 483 remaining L1-negative cases were re-tested using E6/E7 type specific primers, and 89 additional cancer cases were detected. This corresponds to an 18% (89/483) improvement or a 3.2% (89/2806) gain in overall HPV-negative cancer detection using just the HPV16/18 target regions (65% of the cancer cases in the study cohort). If one assumes an equal detection rate for all 14 high-risk types, this would result in an approximately 4.9% (136/2806) improvement in overall cancer detection. Thus, based on this large cancer cohort (representing approximately 1.57 million screened women),²² an estimated 28% (136/483) increase in HPV-negative cancer detection might be obtained using E6/E7 versus L1 primer sets.

While it is not possible to detect all cancer using either cytology and or HPV testing, there is little doubt that HPV testing is the most sensitive tool. In addition to the Ronco et al²³ study cited by Zeferino and colleagues, Schiffman et al²⁴ performed a comprehensive analysis in a cohort of over 1.2 million women with screening histories preceding cancers ($n = 623$) and precancers ($n = 5369$). They found that HPV testing identified more women subsequently diagnosed with cancer ($P < 0.001$) and precancer ($P < 0.001$), except for within 12 months when cytology showed improved cancer detection ($P = 0.10$). However, this represented, at most, 5 cases per million women per year, and the authors questioned the utility of continued co-testing versus primary HPV screening – “Excessive screening in an attempt to prevent every case could have minimal cancer prevention benefits while increasing the harms of screening”.

The decision on which screening paradigm to adopt is often driven by both the science as well as regional or country-

specific parameters, including infrastructure, societal risk tolerance, and funding/reimbursement. However, it is important that clinicians and decision makers carefully weigh the safety and effectiveness of different approaches so as to maximize the impact of any screening program. Adenocarcinomas continue to represent a significant screening challenge, but it is hoped that with advancements in screening tools and the impact of vaccination, this performance gap will soon begin to close.

Finally, the issue with HPV- negative cervical adenocarcinoma poses both a challenge for cervical cancer screening programs and an important scientific and clinical question about the etiology of cervical glandular lesions. In our opinion, this situation necessitates a “call to arms” within the scientific and clinical community, in which a systematic investigation of cervical adenocarcinoma cases using deep nucleic acid sequencing analysis is warranted to answer the question about HPV association with all cervical adenocarcinomas. It is likely that these studies will lead to next generation cervical cancer screening technologies and improved adenocarcinoma detection.

Authors' Reply

Dear Editor,

We are grateful for the insightful comments made by the authors and the well-structured review of literature, which indicates a new step on the debate of cervical cancer screening. The detection of adenocarcinomas represents a challenge for cervical cancer screening programs, and the performance of HPV tests on preventing them is debatable.

Even considering these issues, in regions where the incidence of cervical cancer is middle or high, the robust evidence about the DNA-HPV test performance supports the recommendations for implementing this technology instead of cytology, as long as accompanied by improvements on the programmatic strategy to ensure access and high coverage for the target population.

It is clear that the benefits observed in the first stage of the HPV-DNA test implementation will be more evident in the control of squamous neoplasms. In the second stage, it is possible that the limitations pointed out in the detection of glandular neoplasia will be more evident. This debate is fairly current in countries with low rates of cervical cancer, which have already had controlled incidence rates.

In middle-income countries such as Brazil, where the incidence of squamous cell carcinoma is high, the impact of the implementation of HPV test-based screening surpasses the doubtful HPV test performance on detecting cervical adenocarcinoma. By now, it may only indicate a reduction in expectations regarding the impact to be observed with the new technique.

In the near future, new screening technologies might overcome these limitations. In addition, ongoing vaccination policies may contribute to reduce the impact of this issue. A more detailed analysis of the clinical and biomolecular characteristics of endocervical adenocarcinomas is quite opportune. Furthermore, a better understanding of such characteristics could provide new tools for screening test and strategies to improve adenocarcinoma detection.

Respectfully,
Zeferino et al

Conflicts of Interest

The authors are employed by Becton Dickinson and Company, which sells and distributes cervical cancer screening products, including the BD Onclarity HPV Assay (Becton Dickinson, Franklin Lakes, NJ, USA), which targets the E6/E7 region of the HPV genome.

References

- Segura MEA. Comments on: limitations of HPV DNA testing in screening of cervical adenocarcinomas. *Rev Bras Ginecol Obstet* 2019;41(02):133–134. Doi: 10.1055/s-0039-1678591
- Zeferino LC, Bastos JB, Vale DBAPD, et al. Guidelines for HPV-DNA testing for cervical cancer screening in Brazil. *Rev Bras Ginecol Obstet* 2018;40(06):360–368. Doi: 10.1055/s-0038-1657754
- Smith MA, Canfell K. Projected impact of HPV vaccination and primary HPV screening on cervical adenocarcinoma: Example from Australia. *Papillomavirus Res* 2017;3:134–141. Doi: 10.1016/j.pvr.2017.04.003
- Katki HA, Kinney WK, Fetterman B, et al. Cervical cancer risk for women undergoing concurrent testing for human papillomavirus and cervical cytology: a population-based study in routine clinical practice. *Lancet Oncol* 2011;12(07):663–672. Doi: 10.1016/s1470-2045(11)70145-0
- Zheng B, Li Z, Griffith CC, et al. Prior high-risk HPV testing and Pap test results for 427 invasive cervical cancers in China's largest CAP-certified laboratory. *Cancer Cytopathol* 2015;123(07):428–434. Doi: 10.1002/cncy.21557
- Tao X, Griffith CC, Zhou X, et al. History of high-risk HPV and Pap test results in a large cohort of patients with invasive cervical carcinoma: experience from the largest women's hospital in China. *Cancer Cytopathol* 2015;123(07):421–427. Doi: 10.1002/cncy.21545
- Petry KU, Liebrich C, Luyten A, Zander M, Iftner T. Surgical staging identified false HPV-negative cases in a large series of invasive cervical cancers. *Papillomavirus Res* 2017;4:85–89. Doi: 10.1016/j.pvr.2017.10.003
- Molijn A, Jenkins D, Chen W, et al; Chinese HPV Typing Group. The complex relationship between human papillomavirus and cervical adenocarcinoma. *Int J Cancer* 2016;138(02):409–416. Doi: 10.1002/ijc.29722
- Tjalma WA, Depuydt CE. Cervical cancer screening: which HPV test should be used—L1 or E6/E7? *Eur J Obstet Gynecol Reprod Biol* 2013;170(01):45–46. Doi: 10.1016/j.ejogrb.2013.06.027
- Petry KU, Cox JT, Johnson K, et al. Evaluating HPV-negative CIN2+ in the ATHENA trial. *Int J Cancer* 2016;138(12):2932–2939. Doi: 10.1002/ijc.30032
- Karlsen F, Kalantari M, Jenkins A, et al. Use of multiple PCR primer sets for optimal detection of human papillomavirus. *J Clin Microbiol* 1996;34(09):2095–2100
- Pirog EC. Cervical adenocarcinoma: diagnosis of human papillomavirus-positive and human papillomavirus-negative tumors. *Arch Pathol Lab Med* 2017;141(12):1653–1667. Doi: 10.5858/arpa.2016-0356-RA
- Talia KL, Stewart CJR, Howitt BE, Nucci MR, McCluggage WG. HPV-negative gastric type adenocarcinoma in situ of the cervix: a spectrum of rare lesions exhibiting gastric and intestinal differentiation. *Am J Surg Pathol* 2017;41(08):1023–1033. Doi: 10.1097/pas.0000000000000855
- Hu Z, Zhu D, Wang W, et al. Genome-wide profiling of HPV integration in cervical cancer identifies clustered genomic hot spots and a potential microhomology-mediated integration mechanism. *Nat Genet* 2015;47(02):158–163. Doi: 10.1038/ng.3178
- Poljak M, Kocjan BJ, Oštrbenk A, Seme K. Commercially available molecular tests for human papillomaviruses (HPV): 2015 update. *J Clin Virol* 2016;76(Suppl 1):S3–S13. Doi: 10.1016/j.jcv.2015.10.023
- Tjalma WA, Depuydt CE. Cervical atypical glandular cells and false negative HPV testing: a dramatic reality of the wrong test at the right place. *Eur J Gynaecol Oncol* 2014;35(02):117–120. Doi: 10.12892/ejgo24042014
- Nkili-Meyong AA, Moussavou-Boundzanga P, Labouba I, et al. Genome-wide profiling of human papillomavirus DNA integration in liquid-based cytology specimens from a Gabonese female population using HPV capture technology. *Sci Rep* 2019;9(01):1504. Doi: 10.1038/s41598-018-37871-2
- Walboomers JM, Jacobs MV, Manos MM, et al. Human papillomavirus is a necessary cause of invasive cervical cancer worldwide. *J Pathol* 1999;189(01):12–19. Doi: 10.1002/(SICI)1096-9896(199909)189:1<12:AID-PATH431>3.0.CO;2-F
- de Sanjose S, Quint WG, Alemany L, et al; Retrospective International Survey and HPV Time Trends Study Group. Human papillomavirus genotype attribution in invasive cervical cancer: a retrospective cross-sectional worldwide study. *Lancet Oncol* 2010;11(11):1048–1056. Doi: 10.1016/s1470-2045(10)70230-8
- Hopenhayn C, Christian A, Christian WJ, et al. Prevalence of human papillomavirus types in invasive cervical cancers from 7 US cancer registries before vaccine introduction. *J Low Genit Tract Dis* 2014;18(02):182–189. Doi: 10.1097/LGT.0b013e3182a577c7
- Lagheden C, Eklund C, Lamin H, et al. Nationwide comprehensive human papillomavirus (HPV) genotyping of invasive cervical cancer. *Br J Cancer* 2018;118(10):1377–1381. Doi: 10.1038/s41416-018-0053-6
- Hortlund M, Elfström KM, Sparén P, Almstedt P, Strander B, Dillner J. Cervical cancer screening in Sweden 2014–2016. *PLoS One* 2018;13(12):e0209003. Doi: 10.1371/journal.pone.0209003
- Ronco G, Dillner J, Elfström KM, et al; International HPV screening working group. Efficacy of HPV-based screening for prevention of invasive cervical cancer: follow-up of four European randomised controlled trials. *Lancet* 2014;383(9916):524–532. Doi: 10.1016/s0140-6736(13)62218-7
- Schiffman M, Kinney WK, Cheung LC, et al. Relative performance of HPV and cytology components of cotesting in cervical screening. *J Natl Cancer Inst* 2018;110(05):501–508. Doi: 10.1093/jnci/djx225