

Sonographic Cervical Shortening after Labor Induction is a Predictor of Vaginal Delivery

Ultrassonografia para encurtamento do colo do útero após indução de parto é um preditor de parto normal

Ugo Indraccolo¹ Gennaro Scutiero² Pantaleo Greco²

¹ Complex Operative Unit of Obstetrics and Gynecology, Alto Tevere Hospital of Città di Castello, Città di Castello (PG), Italy

² Section of Obstetrics and Gynecology, Department of Morphology, Surgery and Experimental Medicine, University of Ferrara, Cona (FE), Italy

Address for correspondence Ugo Indraccolo, MD, PhD, Complex Operative Unit of Obstetrics and Gynecology, Alto Tevere Hospital of Città di Castello, Via P. Veronese 2/c, 06024 Gubbio (PG), Italy (e-mail: ugo.indraccolo@libero.it).

Rev Bras Ginecol Obstet 2016;38:585–588.

Abstract

Objective Analyzing if the sonographic evaluation of the cervix (cervical shortening) is a prognostic marker for vaginal delivery.

Methods Women who underwent labor induction by using dinoprostone were enrolled. Before the induction and three hours after it, the cervical length was measured by ultrasonography to obtain the cervical shortening. The cervical shortening was introduced in logistic regression models among independent variables and for calculating receiver operating characteristic (ROC) curves.

Results Each centimeter in the cervical shortening increases the odds of vaginal delivery in 24.4% within 6 hours; in 16.1% within 24 hours; and in 10.5% within 48 hours. The best predictions for vaginal delivery are achieved for births within 6 and 24 hours, while the cervical shortening poorly predicts vaginal delivery within 48 hours.

Conclusion The greater the cervical shortening 3 hours after labor induction, the higher the likelihood of vaginal delivery within 6, 24 and 48 hours.

Keywords

- ▶ cervical shortening
- ▶ delivery outcome
- ▶ transvaginal ultrasonography
- ▶ labor induction

Resumo

Objetivo Analisar se a avaliação ultrassonográfica do colo do útero (encurtamento) é um marcador prognóstico para parto normal.

Métodos Consideramos mulheres com trabalho de parto induzido usando dinoprostona. Antes da indução e três horas após, a extensão cervical foi medida por ultrassonografia para obter o encurtamento do colo do útero. O encurtamento do colo do útero foi aplicado em modelos de regressão dentre variáveis independentes. Curvas de Característica de Operação do Receptor foram calculadas.

Resultados Cada centímetro no encurtamento do colo do útero aumenta as chances de parto normal para 24,4% dentro de 6 horas; 16,1% dentro de 24 horas; e 10,5% dentro de 48 horas. Os melhores preditores de parto normal são alcançados para partos dentre 6 e 24 horas, enquanto o encurtamento prevê mal o parto normal dentro de 48 horas.

Palavras-chave

- ▶ encurtamento do colo do útero
- ▶ resultado do parto
- ▶ ultrassonografia transvaginal
- ▶ indução do parto

received
May 16, 2016
accepted
November 8, 2016
published online
December 19, 2016

DOI <http://dx.doi.org/10.1055/s-0036-1597629>.
ISSN 0100-7203.

Copyright © 2016 by Thieme-Revinter
Publicações Ltda, Rio de Janeiro, Brazil

License terms



Introduction

Cervical length assessment prior to induction is a component of Bishop's score that is already used to predict the success of the labor induction. A meta-analysis supports the ability of Bishop's score in predicting the success of labor induction.¹ The rationale of the clinical cervical length assessment has been translated in the practice to assess the cervical length by sonography. Several studies support that sonographic cervical assessments are predictors of the success of the induction,^{2,3} but there is no consensus regarding transvaginal ultrasonography as a predictor of the success of the induction. Moreover, to the best of our knowledge, only the study conducted by Kang et al⁴ has investigated the value of changes in the length of the cervix in predicting the success of the induction.

The aim of this short report is to demonstrate that the cervical shortening, as assessed by sonography, is a predictor for the success of the induction of labor. This additional evidence may be used in meta-analyses.

Methods

A sample of women undergoing labor induction for many indications by using dinoprostone (0.5 mg/3 ml – Pfizer Italia srl) intracervically were enrolled in the Obstetric and Gynecological Unit of University of Foggia (Ospedali Riunti di Foggia) between October 2006 and April 2008. The patients provided their consent to undergo transvaginal ultrasonography before and after labor induction for cervical assessment. Before the induction, the cervix was measured by taking a sagittal scan from the inner os to the vaginal edge. Three hours after the induction, the same assessment was repeated. The patients were enrolled during the shifts of two Authors (UI and GS), who were able to repeat the measurements in the succeeding hours after labor induction. The measurements were collected with the transvaginal probe of the sonograph (Aloka 5500, ALOKA CO. LTD, Tokyo, Japan) set at 160° and 27 Hz, with the patient in the dorsal lithotomic position.

The length measured after the induction was subtracted from the value of the length measured before the induction in order to obtain the cervical shortening. This cervical shortening was introduced in the logistic regression analyses to calculate the odds ratios for vaginal delivery within 6, 12, 24 and 48 hours after the labor induction. Cervicometry before induction, multiparity, oxytocin infusion, and more administrations of prostaglandin agonists were also independent variables.

Receiver operating characteristic (ROC) curves were also calculated in order to assess the success of the prediction for the cervical shortening and the likelihood of a vaginal delivery within 6, 12, 24 and 48 hours.

The Statistical Package for the Social Sciences (SPSS) software version 16.0 was used for the calculations. Alpha was set as < 0.05 . The study was approved by the local Ethics Committee.

Results

A sample of 63 women was enrolled (with a mean age of 28.3 years, 95% confidence interval [CI]: 26.9–29.6 years). 16 patients (25.4%) were multiparas (10 patients with only 1 previous vaginal birth; 5 patients with 2 previous vaginal births; and 1 patient with 3 previous vaginal births). The mean gestational age was 283.8 days (95% CI: 282.4–285.2 days). Inductions were indicated for patients: with over 41 weeks of gestation (20 patients – 31.7%); in the 41th week of gestation (15 patients – 23.8%); with premature rupture of membranes (14 patients – 22.2%); with hypertensive disorders of the pregnancy (2 patients – 3.2%); with sonographic diagnosis of intrauterine growth restriction or large for gestational age baby (5 patients – 7.9%); with oligohydramnios, or abnormal cardiotocographic patterns, or reduction of fetal movements (10 patients – 15.9%). Sometimes, the indications for the inductions overlapped.

A total of 27 patients (42.9%) underwent cesarean sections, while vacuum delivery was needed in 1 case (0.02%). The indications for cesarean section were: obstructed labor (15 cases – 55.5%); abnormal cardiotocographic patterns (9 cases – 33.3%); and induction failure (4 cases – 14.8%). In one case, both dystocia and abnormal fetal heart rate were found. The indication for the vacuum delivery was failure to progress.

► **Table 1** reports the adjusted odds ratios of the logistic regression analyses along with the descriptive statistics. The cervical shortening after the first administration of intracervical dinoprostone is an independent predictor of delivery within 6, 24 and 48 hours, while multiple administration of intracervical dinoprostone increases the odds ratios of vaginal delivery within 12 and 24 hours. Each centimeter in the cervical shortening increases in 24.4% the odds of vaginal delivery within 6 hours; in 16.1% the odds of vaginal delivery within 24 hours; and in 10.5% the odds of vaginal delivery within 48 hours.

The areas under the curves (AUCs) for the cervical shortening are: delivery within 6 hours – 0.784 (standard error: 0.160, $p = 0.036$, ► **Fig. 1**); delivery within 12 hours – 0.621 (standard error: 0.100, $p = 0.160$, ► **Fig. 2**); delivery within 24 hours – 0.690 (standard error: 0.081, $p = 0.014$, ► **Fig. 3**); and delivery within 48 hours – 0.630 (standard error: 0.071, $p = 0.076$, ► **Fig. 4**).

Discussion

Many studies have assessed the ability of transvaginal ultrasound examination of the cervix in predicting the successful outcome of induced labors. A wide review of these studies was recently done by Papillon-Smith and Abenheim.⁵ Some authors have assessed the cervical length parameter alone or in combination with other maternal characteristics for predicting the outcome of induction, while others have compared the ultrasonographic cervical length versus the digital examination as a predictor of the success of the induction. The level of heterogeneity among the studies makes it difficult to conclude that ultrasonography cervical length is suitable for wide

Table 1 Descriptive statistics and results of the logistic regression analyses (adjusted odds ratio with 95% confidence intervals)

		Vaginal delivery within 6 hours	Vaginal delivery within 12 hours	Vaginal delivery within 24 hours	Vaginal delivery within 48 hours
	means ± SD	OR 95% CI of OR p			
Cervical shortening	6.88 ± 6.49 mm	1.244 1.030–1.503 0.024*	1.060 0.947–1.187 0.308	1.161 1.029–1.310 0.016*	1.105 1.010–1.209 0.030*
Cervicometry before induction	26.21 ± 10.44 mm	0.823 0.673–1.007 0.058	0.940 0.862–1.024 0.156	0.933 0.859–1.014 0.103	0.953 0.888–1.022 0.180
	rate (%)	OR 95% CI of OR p			
Multiparity	25.4%	0.490 0.008–30.962 0.736	3.320 0.527–20.919 0.201	2.791 0.556–14.002 0.212	2.298 0.624–8.465 0.211
Oxytocin infusion	65.1%	0.589 0.006–55.752 0.819	1.249 0.219–7.120 0.802	1.211 0.284–5.169 0.796	2.505 0.815–7.701 0.109
> 1 dose of dinoprostone	44.5% – 2 doses 11.1% – 3 doses	Unreliable	0.029 0.004–0.246 0.001*	0.197 0.053–0.727 0.015*	1.065 0.326–3.476 0.917

Abbreviations: CI, confidence interval; OR, odds ratio; SD, standard deviation.
*significant results.

clinical use,⁵ and a recent meta-analysis of two randomized trials⁶ does not prove the superiority of the ultrasonography versus Bishop’s score. Even the elastosonography of the cervix has received some criticism regarding the prediction of the outcome of the induction.⁷ Moreover, if the induction is needed, unfavorable ultrasonographic findings and

unfavorable Bishop’s scores do not change the clinical management of the patients. Practicing obstetricians need a tool to check the effectiveness of the first dose of prostaglandin agonists administered for labor induction, and ultrasonography cervical shortening seems the easier and more precise tool.

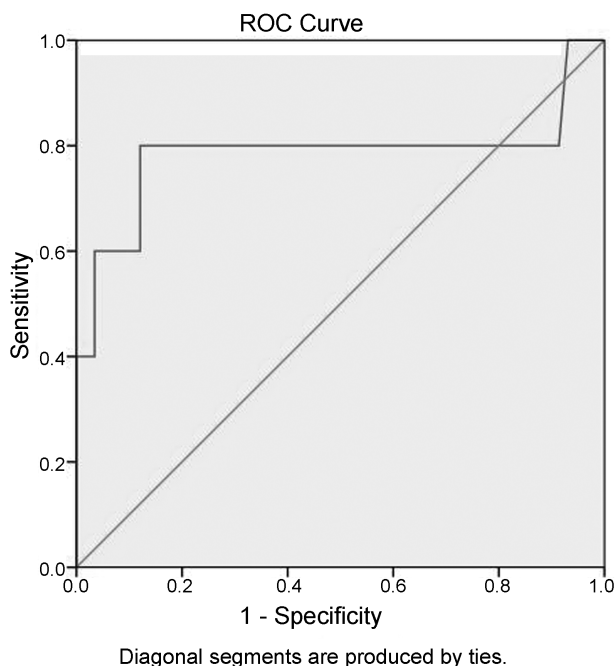


Fig. 1 Receiver operating characteristic (ROC) curve for delivery within 6 hours.

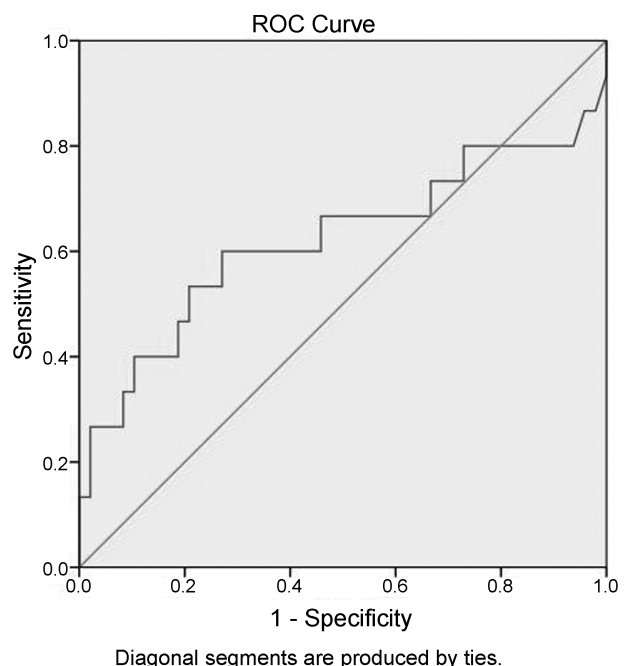


Fig. 2 Receiver operating characteristic (ROC) curve for delivery within 12 hours.

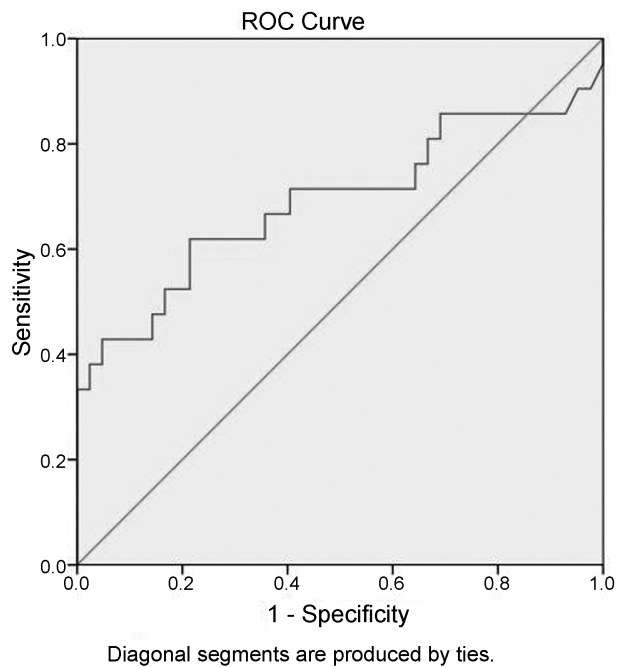


Fig. 3 Receiver operating characteristic (ROC) curve for delivery within 24 hours.

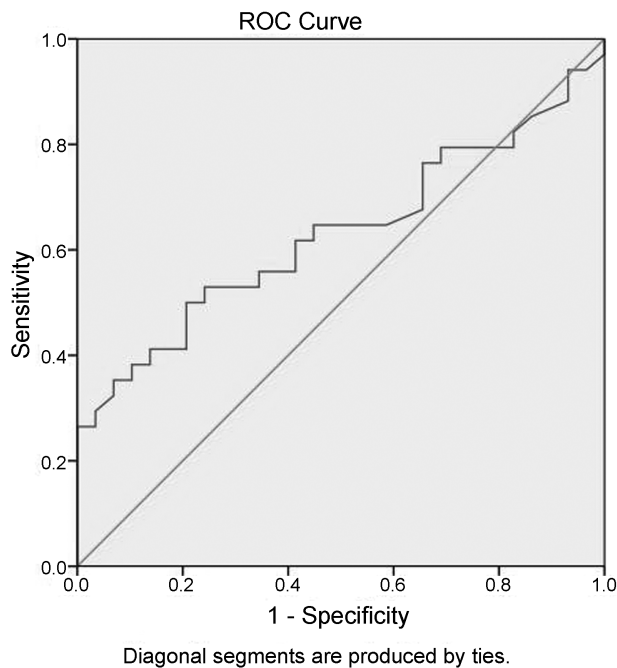


Fig. 4 Receiver operating characteristic (ROC) curve for delivery within 48 hours.

This short report confirms what was already reported by Kang et al⁴ in a wider sample of women with induced labors. Therefore, despite the biases related to the low sample size and the heterogeneity of the patients with induced labor in our study, we must reiterate the conclusion reached by Kang et al⁴: the presence of cervical shortening after the first induction is a predictor of a successful delivery if the induction was repeated in the second day.

By assessing the AUCs, we found that the best predictions for vaginal delivery are achieved for births within 6 and 24 hours, while the cervical shortening poorly predicts vaginal delivery within 48 hours. Whether patients with poor cervical shortening (less than 1 cm) 3 hours after induction should postpone the induction rather than receive more doses of dinoprostone should be assessed. A randomized trial should clarify this concern, in order to avoid the harms that come from the unnecessary use of prostaglandin agonists in patients who are not responsive to them.

In conclusion, the greater the sonographic cervical shortening 3 hours after labor induction, the higher the likelihood of vaginal delivery within 6, 24 and 48 hours.

This study was performed at the Institute of Obstetrics and Gynecology, Department of Surgical Sciences, University of Foggia (via Pinto – 71100, Foggia, Italy) during the shifts of the Authors. The Authors do not travel currently to the University of Foggia.

References

- 1 Teixeira C, Lunet N, Rodrigues T, Barros H. The Bishop Score as a determinant of labour induction success: a systematic review and meta-analysis. *Arch Gynecol Obstet* 2012;286(3):739–753
- 2 Verhoeven CJ, Opmeer BC, Oei SG, Latour V, van der Post JA, Mol BW. Transvaginal sonographic assessment of cervical length and wedging for predicting outcome of labor induction at term: a systematic review and meta-analysis. *Ultrasound Obstet Gynecol* 2013;42(5):500–508
- 3 Wozniak S, Czuczwar P, Szkodziak P, Paszkowski T. Usefulness of elastography in predicting the outcome of Foley catheter labour induction. *Aust N Z J Obstet Gynaecol* 2015;55(3):245–250
- 4 Kang WS, Park KH, Kim SN, Shin DM, Hong JS, Jung HJ. Degree of cervical shortening after initial induction of labor as a predictor of subsequent successful induction. *Ultrasound Obstet Gynecol* 2010;36(6):749–754
- 5 Papillon-Smith J, Abenhaim HA. The role of sonographic cervical length in labor induction at term. *J Clin Ultrasound* 2015;43(1):7–16
- 6 Ezebialu IU, Eke AC, Eleje GU, Nwachukwu CE. Methods for assessing pre-induction cervical ripening. *Cochrane Database Syst Rev* 2015;(6):CD010762
- 7 Fruscalzo A, Mazza E, Feltovich H, Schmitz R. Cervical elastography during pregnancy: a critical review of current approaches with a focus on controversies and limitations. *J Med Ultrason* (2001) 2016;43(4):493–504